

Comparative Study of a Novel Tool for Follicular Unit Extraction for Individuals with Afro-textured Hair

Sanusi Umar, MD

Background: Hair transplantation involving patients with tightly curled Afro-textured hair using follicular unit extraction (FUE) employing conventional rotary punches frequently leads to unacceptably high transection rates. These patients are unsuitable candidates for FUE hair transplantation. Transection rates were observed during FUE in a case series of 18 patients with tightly curled Afro-textured hair using different punches.

Methods: Three different punches were sequentially used in patients to extract follicular units with several needle gauges until satisfactory transection rates occurred: conventional sharp and dull rotary punches, followed by a 2-pronged curved nonrotary punch.

Results: In all instances, the curved nonrotary punch had the best transection rate of <5%. Sharp and dull rotary punches completely failed or had excessive transection rates in 8 patients. The dull rotary punch performed better than the sharp rotary punch in 9 patients in whom it was used with few restrictions compared to 5 patients in whom there were more restrictions.

Conclusions: A curved nonrotary punch configured to accommodate the curliness of tightly curled Afro-textured hair can overcome high transection rates experienced using conventional sharp or dull rotary punches. Limitations of this study include it being a small, retrospective case series, and that the new technique that could require additional training by current FUE hair transplant practitioners. (*Plast Reconstr Surg Glob Open* 2016;4:e1069; doi: 10.1097/GOX.0000000000001069; Published online 27 September 2016.)

Follicular unit extraction (FUE) is a minimally invasive method of hair transplantation that avoids the creation of a linear scar and is increasingly the method of choice for patients. To date, conventional FUE involves the use of sharp- or dull-edged punches to score around the hair follicles at varying depths to substantially free it from tissue attachments. This scoring is done by a complete, partial, or oscillatory rotary cutting action created by a tubular punch edge circled around the follicle.

The cutting action in these methods follows a transverse axial plane relative to the follicular shaft. After scoring, the follicle is pulled free using fine forceps with or without the aid of further dissection of any remaining tissue attachments of tethered grafts.

Practitioners of conventional FUE are aware of the challenges posed by hair curliness and tissue characteristics that may cause traumatic damage to extracted grafts. The damage is quantified by the transection rate, defined as the ratio of the number of extracted follicles that are accidentally cut and damaged during FUE to the total number of grafts extracted. As a result, patients with tightly curled hair are often considered poor candidates for conventional FUE.¹⁻⁴ Most patients with the most tightly curled hair are of African descent⁵⁻⁷ but these individuals are not a homogenous group, with variation in degree of

From the Dermatology Division, Department of Medicine, University of California at Los Angeles, Calif.; and FineTouch Dermatology, Inc., Redondo Beach, Calif.

Received for publication July 20, 2016; accepted August 12, 2016.

Copyright © 2016 The Author. Published by Wolters Kluwer Health, Inc. on behalf of The American Society of Plastic Surgeons. All rights reserved. This is an open-access article distributed under the terms of the Creative Commons Attribution-Non Commercial-No Derivatives License 4.0 (CCBY-NC-ND), where it is permissible to download and share the work provided it is properly cited. The work cannot be changed in any way or used commercially.

DOI: 10.1097/GOX.0000000000001069

Disclosure: The author holds US patents, has additional patent applications for the UGraft and UPunch technologies described in this article, and is employed by FineTouch Dermatology, Inc. The Article Processing Charge was paid for by the author.

curliness between groups from different countries.^{5,6} Variations also exist in the same individual when hair is taken from different scalp regions.⁷ All these variations reflect both ethnic mixing (often for Africans in diaspora such as the United States and the Caribbean) that has occurred over generations and genetic variations that track closely the migratory paths taken in the out-of-Africa migration that occurred over 100,000 years ago.⁵⁻⁷ This issue presents a special challenge for most men with tightly curled Afro-textured hair who seek hair transplants and typically prefer a shorter haircut; these individuals stand to benefit the most from having an FUE procedure to avoid a linear scar associated with follicular unit strip surgery.

Whether an Afro-textured-haired patient is a good candidate for FUE is uncertain; hence, some FUE providers conduct a small initial test in which the surgeon takes out a few (about 100) grafts from the donor area and then evaluates how many complete/incomplete follicular units are extracted. This test requirement comes with some inconveniences to the patient, who has to schedule an additional procedure if successful.

In a single case report, Singh and Avram³ suggested methods for improving the transection rate of conventional FUE in Afro-textured hair that included (1) limiting the depth of the first score incision and (2) increasing the punch size to a diameter that is large enough to encompass the amplitude of the subcutaneous curl wave of the follicle (greater than the diameter of the C). However, in Dr Umar's experience, substantially limiting the depth of the initial score increases the effort needed to separate the remaining tissue attachments of the follicle, causing increased stress and trauma to the grafts and significantly increasing surgery time. In addition, increasing punch sizes to accommodate the subcutaneous amplitude of the curl wave of the grafts could result in unacceptably large punch sizes, having to be deployed in many instances in which the diameter of the C is significant (3–4 mm or more in some patients; Fig. 1) with the risk of unacceptable scarring sequelae.

The objective of this retrospective study is to present the author's experience in using a novel tool and methodology for performing FUE in Afro-textured hair and quantification of the transection rate of the extracted hair shafts using different approaches.

MATERIALS AND METHODS

This study was a retrospective case series of outcomes in 18 patients of African descent or nationalities with tightly curled Afro-textured hair who underwent an FUE procedure between January 14, 2014, and November 14, 2015, at the author's dermatology clinic. Written informed consent for surgery was obtained.

General FUE Technique

In each patient, punches were tried in the following sequential order until a satisfactory transection rate was attained: sharp rotary punches (18, 17, and 16 gauge), dull rotary punches (17 and 16 gauge), and curved nonrotary punches (17 and 16-gauge). When success was first

achieved with a rotary sharp or dull punch (satisfactory transection rate with no restrictions on donor area), the procedure was considered complete with the smallest sharp or dull punch that worked best. However, a test extraction of 100 or more grafts was also then conducted with the curved nonrotary punch.

In all instances, FUE was accomplished under local anesthesia by subcutaneous injections of epinephrine (1:100,000) and lidocaine 1%, and bupivacaine hydrochloride 0.25% without tumescence. For recipient grafting, slits were created by means of blades that are custom sized to the dimensions of the extracted grafts. Main outcomes were transection rates of extracted hair shafts for each of the approaches tried for each patient.

Rotary Punch Technique (Sharp and Dull)

The general technique used by the author for FUE by the rotary punches has been described previously.⁸ In brief, the punch was mounted on an electromechanical drill that rotates the punch, such that when the punch edge is applied circumferentially around the hair follicles, it creates an incision that scores along a transverse axis to substantially separate the grafts from its surrounding tissue attachments. Next, hair follicles were subsequently removed with the occasional assistance of hypodermic needle-tip dissection and placed in chilled Ringer's lactate solution. The rotary punches used by the author consisted of custom-fabricated hypodermic needles whose tips were modified to impart a circumferential flare outward to form a punch-like instrument (UPunch Rotor, fabricated in the author's office). Because the axis of the punch-cutting edges is directed away from the follicles (Fig. 2), much of the customary graft damage that accompanies use of straight punches is minimized.⁸ Sharp punches were

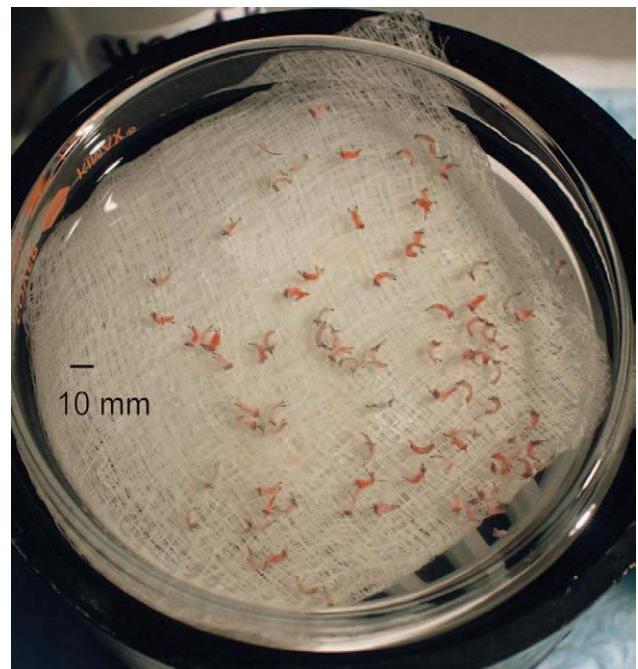


Fig. 1. Grafts extracted using the curved nonrotary punch in a studied patient. The diameter of C is >3 mm in many of the grafts.

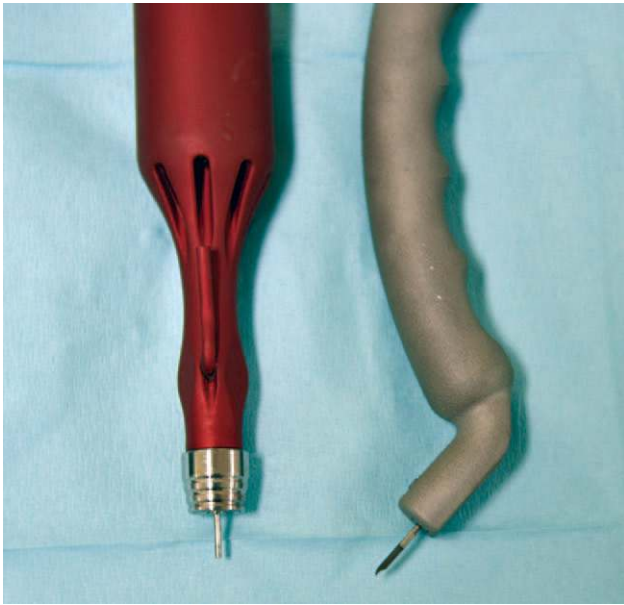


Fig. 2. Pictures of the sharp rotary punch and curved nonrotary punch (from left to right).

constructed from 16-, 17-, or 18-gauge needles, whereas dull punches were fabricated from 16- or 17-gauge needles (Fig. 2). Grafts were irrigated at the time of scoring using an automated device (UGraft Revolution prototype by Keck Craig, Inc., Pasadena, Calif.).

Nonrotary Curved Punch Technique (Nonrotary)

Nonrotary curved punches (the UPunch Curl) were developed by the author and prototyped by Keck Craig, Inc. (Pasadena, Calif.; Fig. 2). The two tips of the prongs are positioned to straddle either side of the follicle to a skin depth of 1–2 mm at angles of 10–15 degrees from the scalp plane. The long axis of the punch is first aligned with the direction of the hair as it exits the skin. The tip of the hook-shaped punch is plunged subcutaneously in a quick, arc-like motion that follows the general curl of the curved punch tip. The cutting axis thus tracks the longitudinal axis of the curled hair follicle shaft subcutaneously. The punch is pushed to the base of the follicles or even

deeper, at which point the follicle is seen to pop out of the skin. Typically, the follicle stays loosely tethered to the extraction hole and is easily pulled out using microvascular forceps. Alternatively, it can attach to the punch, in which case the fluid mechanism is employed to flush the graft into a Petri dish by aid of a foot-pedal-activated flushing system that discharges a pulse of physiologic solution to the tip of the punch (Fig. 3). In both instances, no further dissection is typically required.

Mechanistic Differences between Rotary FUE Punches and the Curved Nonrotary Punch

Rotary punches have a cutting edge (sharp, blunt, flat, or serrated) that runs through the entire circumference of the tube on the same plane. Thus, the cutting action of the rotary punches is along a transverse axis generated by rotary or oscillatory motion of the cutting edge along the complete circumference of the circular edge. The circular cut is carried down the long axis of the hair follicle from the skin surface toward the hair bulb. If the graft is tightly curled as is the case in many Afro-textured hair, it is susceptible to transection. The curved nonrotary punch has a tip that is configured to make allowance for the curliness of the hair, with a strategically situated U-shaped cut along the circumference of the tubular edge. This is further aided by the cutting action generated in a plunging action along the longitudinal axis of the curled follicle shaft, thus approximating better the natural curly subcutaneous course of the follicle (Fig. 3).

RESULTS

Patient 10

A 48-year-old male patient from the Bahamas with tightly curled Afro-textured hair presented with Norwood 3 (NW3) androgenic alopecia for FUE-type hair transplant to avoid the linear scarring of follicular unit strip surgery. The use of a 17-gauge sharp rotary punch mounted on a rotary device resulted in <10% transection rate in a 5–6 cm corridor of the mid-occipital areas. The transection rate, however, rose significantly (60%–80%) when extractions were carried into safe donor areas (SDAs) lateral to this narrow corridor toward the parietal areas. The transection

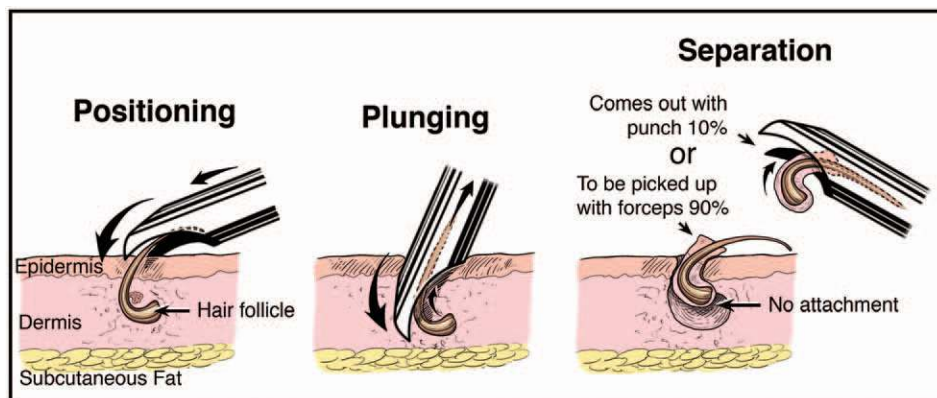


Fig. 3. Depiction of the hair follicle extraction process using the curved nonrotary punch.

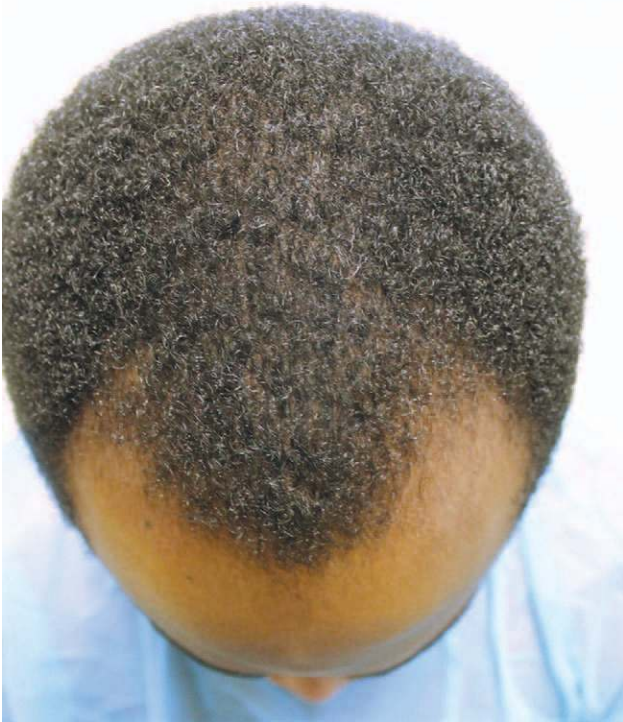

Fig. 4. Front view of patient 7 (aged 27 years) showing NW 3 recession.

rate remained similarly high with the use of a dull version of the 17- and 16-gauge rotary punches. However, when a 17-gauge nonrotary curved punch was deployed, a transection rate of <5% in all the areas of the SDA was observed.

Patient 7

A 27-year-old male patient from Cameroun with tightly curled Afro-textured hair presented with NW3 androgenic alopecia for FUE-type hair transplantation (Fig. 4). He also had linear scarring from an earlier failed follicular unit strip surgery. The use of a 17- and 16-gauge sharp punch resulted in ~90% transection rate in all areas of the SDA. The use of a dull rotary punch (16 gauge) improved the transection rate to about 20%, but a 17-gauge nonrotary curved punch resulted in a transection rate of <5% in all areas of the SDA. After 2 surgeries about 7 months apart in which 1,042 and 652 hair grafts were transplanted, respectively (Figs. 5 and 6), the patient's hairline was restored (Fig. 7) with the donor areas being perfectly presentable.

Patient 3

A 42-year-old African American patient with noninflammatory cicatricial alopecia previously underwent a conventional FUE elsewhere with disappointing results (Fig. 8). Use of a 16-gauge sharp and dull rotary punch resulted in high transection rate of >80%. Upon using the 16-gauge curved nonrotary punch, however, the transection rate was dramatically reduced to <5% throughout the SDA with satisfactory result and growth reported at 1 year after 2 surgeries (Figs. 9 and 10).

All Results

A successful transection rate was considered <10% for the 18 patients in this case series, defined before analysis of the patient data. The sharp and dull rotary punches did not work at all or had excessive transection rates for 8 patients, with results vastly superior when the nonrotary curved punch was used (Table 1). The dull rotary punch performed better than the sharp rotary punch in 9 patients in whom it was used with few restrictions when compared to 5 patients in whom it was used with more restrictions; in all these instances, the curved nonrotary punch had the best transection rate of <5%. Rotary punches (sharp and/or dull) were completely successful in only 4 patients.

DISCUSSION

In all patients in whom the curved punch was eventually used, the transection rate was <10%, and in each individual case of curved punch success, both sharp and dull punches failed after maxing out their sizes with 16-gauge punches. This is the first evidence for eliminating the consideration of punch size as the cause for the difference in performance and transection rates. In all patients in whom the curved punch was used, the approach for initially limiting the depth of the first score using rotary punches (sharp or dull) also failed as it did not improve the graft attrition rate. This approach likely failed because in these patients, the skin is so thick that the amount of manipulation required to carry the

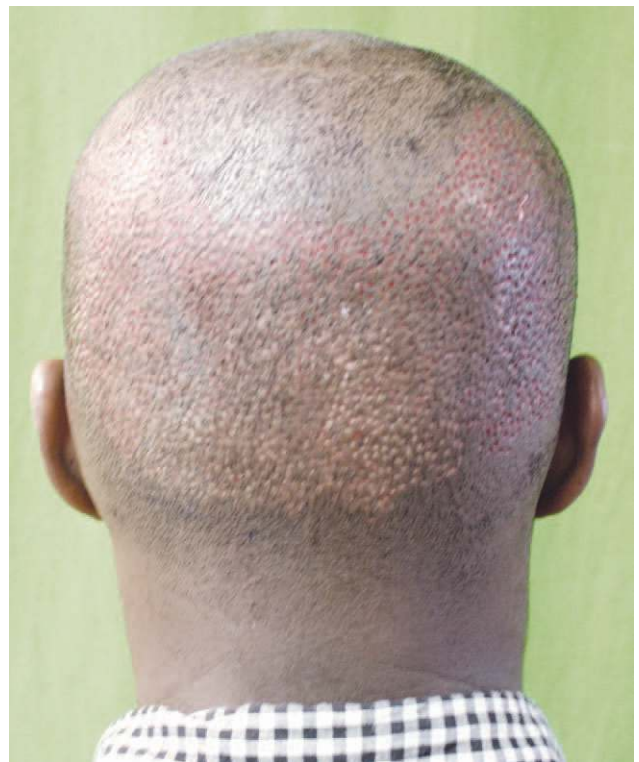


Fig. 5. Rear view of patient 7 (aged 27 years) showing occipital area 1 day after follicular extraction and lateral areas just after follicular extraction.

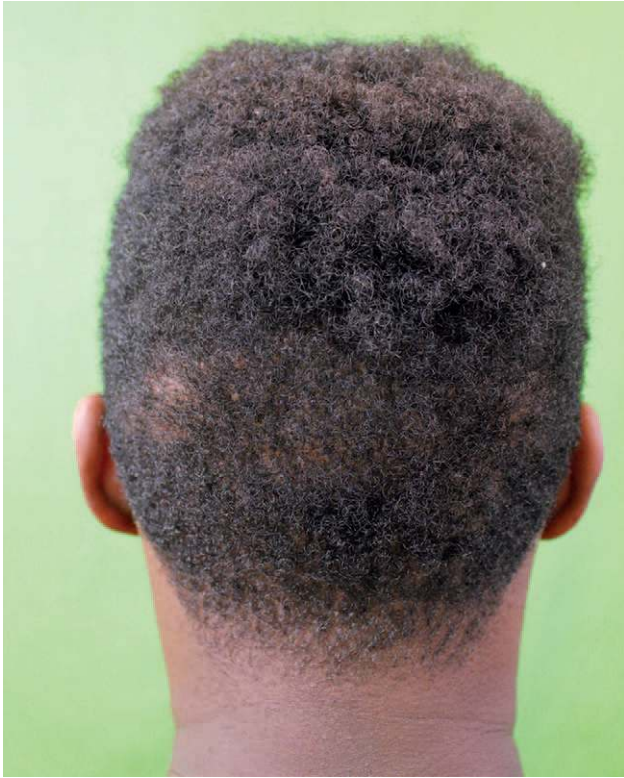

Fig. 6. Rear view of patient 7 (aged 27 years) showing donor areas 12 months after surgery.

dissection and release the graft from its attachments is very high, resulting in grafts that are transected in the process.

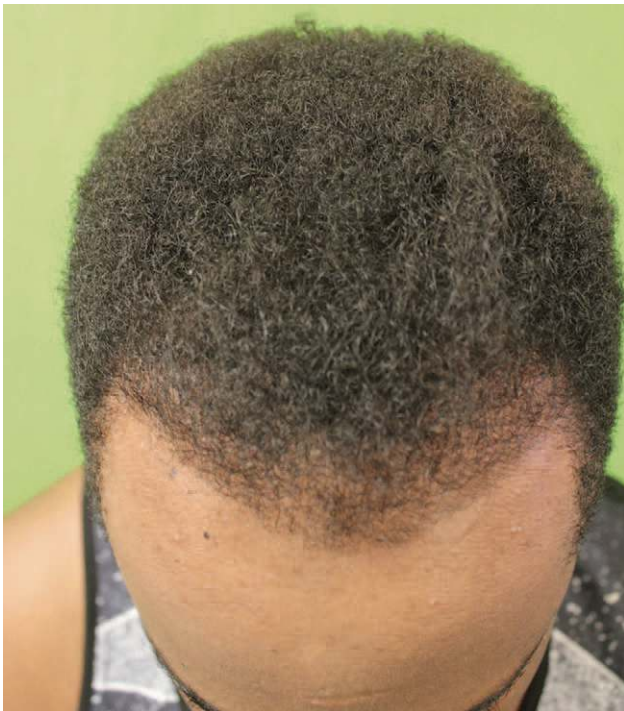

Fig. 7. Frontal view of patient 7 (aged 27 years) showing restored hairline from prior NW3 recession 12 months after FUE.

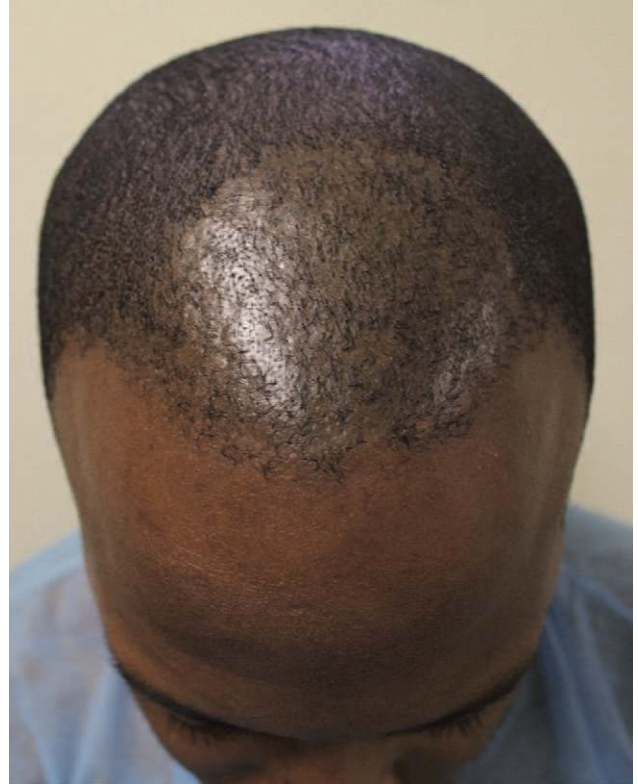

Fig. 8. Front view of patient 3 (aged 42 years) with noninflammatory cicatricial alopecia, showing previous conventional FUE disappointing results.

The observation that Afro-textured-haired individuals responded variably to two different tools (rotary versus nonrotary curved punch) supports earlier studies,^{5,6} which established that worldwide, hair of African-heritage individuals are by no means homogenous. This is due to either mixed ethnic heritage or phenotypic changes that are seen in populations situated in transition zones along the out-of-

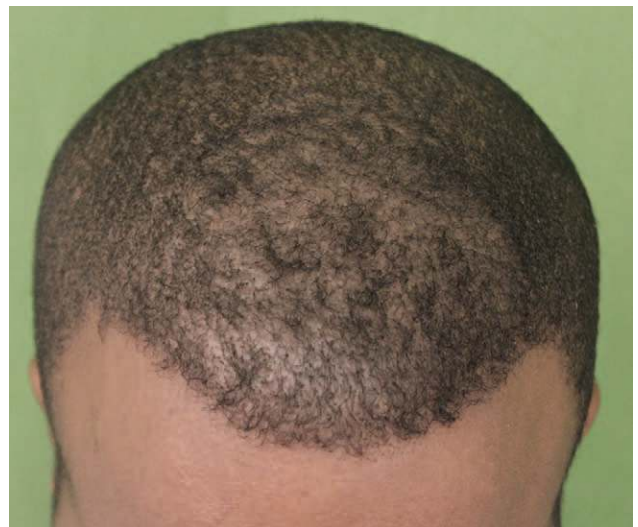

Fig. 9. Patient 3, aged 42 years, 12 months postsurgery, front view.

Table 1. Description of the 18 Patients in the Case Series and Types of Punch(es) Used

Patient	Diagnosis	Ethnicity/ Heritage	Age (y)	Sharp Rotary Punch	Dull Rotary Punch	Curved Nonrotary Punch	Graft Count
1	AKN scar	Nigerian	32	18-G: X 17-G: X 16-G: X	17-G: X 16-G: X*	17-G: X 16-G: ✓	608 (2 sessions)
2	AGA	Nigerian	56	18-G: X 17-G: X 16-G: X	17-G: X 16-G: X	17-G: X 16-G: ✓	3,577 (2 sessions)
3	Cicatricial alopecia	African American	42	18-G: X 17-G: X 16-G: X	17-G: X 16-G: X	17-G: X 16-G: ✓	2,877 (2 sessions)
4†	AGA	Somalian	31	18-G: ✓ 17-G NT: 16-G: NT	17-G: NT 16-G: NT	17-G: ✓ 16-G: NT	1,500
5‡	Traction alopecia	African American	44	18-G: X 17-G: X 16-G: X	17-G: X 16-G: ✓	17-G: ✓ 16-G: NT	979
6	AGA	Nigerian	28	18-G: X 17-G: X 16-G: X	17-G: ✓ 16-G: NT	17-G: ✓ 16-G: NT	2,425 (2 sessions)
7	AGA	Cameroonian	27	18-G: X 17-G: X 16-G: X	17-G: X 16-G: X*	17-G: ✓ 16-G: NT	1,694 (2 sessions)
8	AGA	African American	30	18-G: X 17-G: X 16-G: X	17-G: X 16-G: ✓	17-G: ✓ 16-G: NT	3,153 (2 sessions)
9§	AGA	African American/ mixed heritage	36	18-G: ✓¶ 17-G: X 16-G: X	17-G: ✓ 16-G: NT	17-G: ✓ 16-G: NT	2,645 (2 sessions)
10	AGA	Caribbean/ Bahamas	48	18-G: X 17-G: ✓¶ 16-G: X	17-G: X 16-G: X	17-G: ✓ 16-G: NT	2,345
11	AKN scar	African American	48	18-G: X 17-G: X 16-G: X	17-G: X 16-G: ✓	17-G: ✓ 16-G: NT	2,232
12	AKN scar	African American	32	18-G: X 17-G: X 16-G: X	17-G: X 16-G: X	17-G: X 16-G: ✓	1,152
13	AGA	Ethiopian	29	18-G: X 17-G: ✓¶ 16-G: X	17-G: ✓ 16-G: ✓	17-G: ✓ 16-G: NT	3,446
14	AKN scar	African American	30	18-G: X 17-G: X 16-G: X	17-G: X 16-G: X	17-G: X 16-G: ✓	863
15	AGA	African American	31	18-G: X 17-G: X 16-G: X	17-G: X 16-G: X	17-G: ✓ 16-G: NT	358
16	AKN scar	Caribbean	43	18-G: X 17-G: X 16-G: X	17-G: X 16-G: X	17-G: ✓ 16-G: NT	458
17	Strip surgery scar	African American	44	18-G: ✓ 17-G: NT 16-G: NT	17-G: ✓ 16-G: ✓	17-G: ✓ 16-G: NT	750
18	AGA	African American	44	18-G: NT 17-G: X 16-G: X	17-G: X 16-G: X	17-G: NT 16-G: ✓	277

*Transection rate > 20%.

†Skin was soft.

‡Female.

§SSDA scarred from past FUE surgery.

¶Occipital areas only.

||Parietal areas only.

[X], transection rates of >70%; [✓], satisfactory transection rates of <10%; and [NT], not tried. Bolded symbol [✓] indicates combination used for surgery. Where success was first achieved with a rotary sharp or dull punch (satisfactory transection rate with no restrictions on donor area), the procedure was considered complete with the smallest sharp or dull punch that worked best.

AGA, androgenetic alopecia.

Africa migration paths that go back more than 100,000 years ago. The author’s findings (Table 1) suggest that Afro-textured-haired individuals in diaspora with higher chances of

ethnically mixed heritage (eg, African Americans or Caribbeans) and those who originate from the out-of-Africa migration transition zones (Ethiopians and Somalians) have a

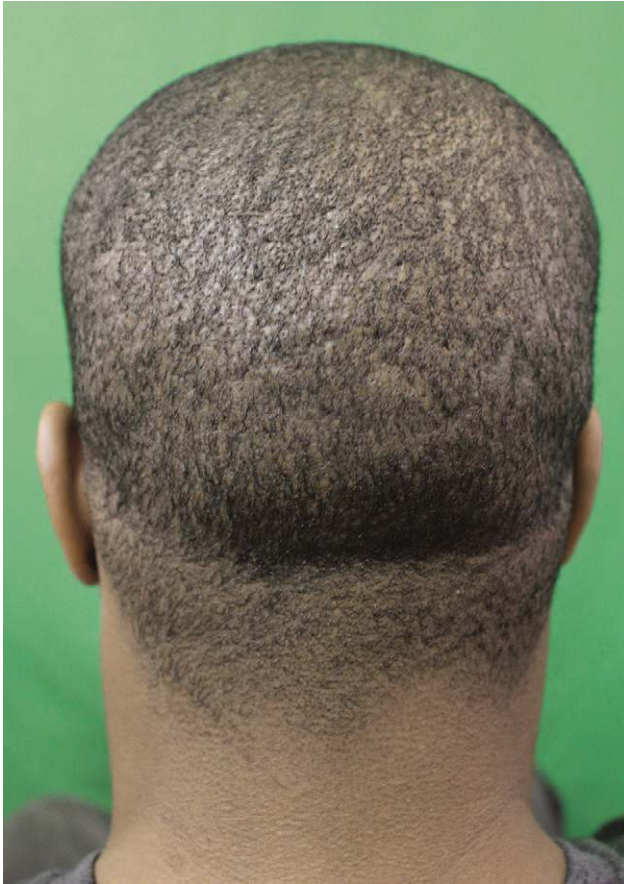

Fig. 10. Patient 3, aged 42 years, 12 months postsurgery, rear view showing donor areas.

higher chance of responding to conventional rotary punches as their follicles tend to be less tightly curled and skin thinner. Furthermore, the variable response to the different tools from one area of the SDA to the other in the same individual (as in patient 1) is supported by the findings of earlier studies.⁶

Although a very small number, there appears to be an anecdotal correlation between the coexistence of acne keloidalis nuchae (AKN) and a high failure rate of rotary punches in FUE techniques. Although the curved punch was successful in all 5 AKN patients, all failed the sharp FUE punch technique and only 1 was successfully done using a dull rotary punch. In addition, the skin in AKN patients was relatively tougher and the hair was curlier subcutaneously compared to the rest of the group (non-AKN patients). In the cases studied thus far, the transection rate for the curved nonrotary punch throughout the SDA in all Afro-textured-haired patients is typically <5%, although in especially challenging patients with AKN, it is <10%. These data suggest that the nonrotary curved punch can be reliably used in FUE procedures for all Afro-textured-haired patients, including the kinkiest-haired patients with coexisting AKN lesions, without the need for pretesting. Furthermore, the curved nonrotary punch procedure is a 1-step FUE method that involves complete separation of the follicle from its attachments in single cutting action,

with minimal need for further dissection and trauma/stress to the grafts. Moreover, there was never any need to exceed the 16-gauge size regardless of the subcutaneous follicular curl wave amplitude (diameter of the C).

Limitations of this study are that it is a small, retrospective case series limited to men and a larger study would be needed to determine the proportions of patients who would respond to rotary punches. It is also a new technique (manual procedure that has not been automated), which could require additional training by current FUE practitioners. The author has also observed that this method is most consistent when the extraction areas are restricted to the SDA and the areas above it. Zones found inferior to the SDA tend to result in increased transection rates. This would thus limit the use of nape and periauricular hair follicles and all the potential benefits accruing from it.⁸⁻¹⁰

CONCLUSIONS

Use of a nonrotary curved punch with a tip configured to accommodate the curliness of tightly curled hair can overcome the high transection rates experienced when using more conventional sharp or dull rotary punches or when these kinds of punches are found to have limitations with specific patients whose hair curliness causes unsatisfactory transection rates.

Sanusi Umar, MD

FineTouch Dermatology Inc.
510N, Prospect Avenue, Suite 209
Redondo Beach, CA 90277
E-mail: drumar@dru.com

ACKNOWLEDGMENT

Figure 3 was conceived and sketched by Dr. Umar but rendered by Kent Broughton of MediVisuals, Inc., Dallas, Tex.

REFERENCES

1. Callender VD, Davis EC. Hair transplantation technique: a flexible blade for preparing curly hair grafts. *Dermatol Surg*. 2011;37:1032–1034.
2. Rogers NE, Callender VD. Advances and challenges in hair restoration of curly Afrocentric hair. *Dermatol Clin*. 2014;32:163–171.
3. Singh MK, Avram MR. Technical considerations for follicular unit extraction in African-American hair. *Dermatol Surg*. 2013;39:1282–1284.
4. Rose PT. Hair restoration surgery: challenges and solutions. *Clin Cosmet Investig Dermatol*. 2015;8:361–370.
5. De la Mettrie R, Saint-Léger D, Loussouarn G, Garcel A, Porter C, Langaney A. Shape variability and classification of human hair: a worldwide approach. *Hum Biol*. 2007;79:265–281.
6. Loussouarn G, Garcel AL, Lozano I, et al. Worldwide diversity of hair curliness: a new method of assessment. *Int J Dermatol*. 2007;46 (Suppl 1):2–6.
7. Porter CE, Dixon F, Khine CC, et al. The behavior of hair from different countries. *J Cosmet Sci*. 2009;60:97–109.
8. Umar S. Use of body hair and beard hair in hair restoration. *Facial Plast Surg Clin North Am*. 2013;21:469–477.
9. Umar S. Eyebrow transplants: the use of nape and periauricular hair in 6 patients. *Dermatol Surg*. 2014;40:1416–1418.
10. Umar S. Use of nape and peri-auricular hair by follicular unit extraction to create soft hairlines and temples: my experience with 128 patients. *Aesthet Surg J*. 2015;35:903–909.